

# Intestinal transplantation: evolution and current status

Jose Renan Cunha-Melo,<sup>1</sup> Guilherme Costa<sup>1</sup>

I - Universidade Federal de Minas Gerais, Department of Surgery, Belo Horizonte, MG, Brazil II - University of Pennsylvania Medical College, Department of Surgery, Pittsburgh, PA, USA

Despite early disappointments, the three main types of visceral transplantation (isolated intestine, liver intestine, and multivisceral) have evolved into the standard of care for patients with nutritional failure and complex abdominal pathology. Visceral allografts have been assessed in clinical, radiological, endoscopic, and histopathologic studies. Absorptive functions of engrafted intestine have been assessed by body weight, body mass index, and z scores, serum levels of albumin, vitamins, and trace elements, as well as measurements of bone mineral density. Allograft rejection, infection, and renal failure, are the leading causes of death. Additionally, nonfunctional social support and progression of primary disease contribute to mortality rates beyond the five- and ten-year follow-up landmarks. Remote events, including acute rejection, post-transplant lymphoproliferative disorder, and graft-versus-host-disease were significantly higher in pediatric recipients. Adult recipients experience higher incidences of *de novo* malignancy, primary disease recurrence, and impaired skeletal health. The leading causes of death are graft failure, complications of therapy, post-transplant lymphoproliferative disorder, progression of primary disease, and others, such as substance abuse, suicide and lack of support. Health status was sustained with successful interventions to treat hypertension, diabetes, osteoporosis, and renal failure. In spite of disease recurrence and long-term immunosuppression-related morbidities, the health status of most survivors has been sustained with successful interventions to treat occurring co-morbidities. With continual improvement in early survival and long-term rehabilitative efficacy, visceral transplantation should be considered a better therapeutic option for patients with severe intestinal failure.

**KEYWORDS:** Intestinal transplantation; Gastrointestinal rehabilitation; Multivisceral transplantation.

Cunha-Melo JR, Costa G. Intestinal transplantation: evolution and current status. MEDICALEXPRESS. 2014;1(6):307-322.

Received for publication on August 23 2014; First review completed on September 9 2014; Accepted for publication on October 4 2014

E-mail: jrcmelo@medicina.ufmg.br

## ■ INTRODUCTION

This article aims to review the evolution and state-of-the-art care of intestinal and multivisceral transplantation. The authors do not intend to extensively review the literature, but rather make readers understand how this difficult medical specialty evolved. The University of Pittsburgh is one of the top institutions in this field, having performed about 600 intestinal transplantations so far, including different modalities of the procedure (intestine-alone, liver-intestine, multivisceral, and modified multivisceral), which corresponds to more than 25% of the world's experience. Therefore, the evolution of the field of intestinal transplantation is mostly based on the experiences at the University of Pittsburgh, as well as on the available literature from other groups when pertinent.

The importance of intestinal transplantation can be demonstrated by the decision of the US Centers for Medicare and Medicaid Services (CMS) in October 2000 to qualify intestinal, combined liver-intestinal, and multivisceral transplantation as the standard of care for patients with

irreversible intestinal failure who no longer can be maintained on total parenteral nutrition (TPN). Therefore, in the past 20 years the clinical reality and reliability of intestinal transplantation was established in the field of organ transplantation.

## ■ BRIEF HISTORY OF INTESTINAL TRANSPLANTATION

The history of intestinal transplantation begins with Alexis Carrel and his description of a method for performing vascular anastomosis. Carrel's pioneering work in experimental surgery, especially in vascular surgery and organ transplantation, earned him the 1912 Nobel Prize in Physiology or Medicine.<sup>1</sup> His initial articles demonstrate his bold yet logical approaches to both the technical and theoretical aspects of organ transplantation. Carrel stated in a publication from 1904 that prior to him, Emerich Ullmann in Austria had conducted similar experiments.<sup>2</sup>

Carrel's technical basis for vascular anastomoses, proposed in 1902, is still valid for all solid organ transplantations, and is based on three main pillars: a) three stitches to change the cylindrical shape of the cut surface of vessels into

DOI: 10.5935/MedicalExpress.2014.06.05

a triangle; b) everting anastomosis; and c) use of very thin suture needles.

Lillehei et al. reported the first canine model of isolated intestinal transplantation in 1959.<sup>3</sup> This was an important landmark in the modern area of intestinal transplantation, because it was the first time that autographs and allografts were preserved by immersion in iced saline; after orthotopic reimplantation the autographs presented good functional capability. The following year, Starzl & Kaupp described a multivisceral transplantation technique in dogs in which the small bowel was transplanted as a composite of abdominal organs. The grafts included the liver, pancreas, stomach, intestine, and colon. Two central arteries, the celiac axis and the superior mesenteric in continuity with the aorta, were joined to the recipient's infrarenal aorta.<sup>4</sup> These two studies, along with a small animal experiment by Monchik and Russel, paved the way for investigations of problems related to intestinal transplantation, such as immunology, immunosuppression, graft preservation, metabolic events, and graft function.<sup>5</sup>

Deterling performed the first human intestinal transplant in Boston. Although he never published this experience, during Alican's discussion of an article on intestinal transplantation at the 11<sup>th</sup> Annual Society for Surgery of the Alimentary Tract Meeting in June 1970 in Chicago,<sup>6</sup> Deterling reported an infant and a young child who had received intestinal transplants at Boston Floating Hospital in 1964. The first was transplanted with a segment of the mother's ileum and died 12 hours later. The second received a cadaveric graft which had to be removed two days later. This patient died a few weeks later. In 1967, Lillehei et al. formally reported the first human intestinal transplant. The vascular reconstruction was performed through donor mesenteric vessels anastomosed to the recipient's left common iliac vessels. The patient died 12 hours later from pulmonary embolism.<sup>7</sup> Olivier et al. (1968) performed what can be considered the first orthotopic intestinal transplantation, as the donor mesenteric vessels were anastomosed to the recipient's mesenteric artery and vein. The patient died 26 days later due to graft rejection. In 1968, Okumura et al. performed the first intestinal transplant in Brazil. The mesenteric vessels were anastomosed to the left iliac vessel, but nine days later the graft was removed due to ischemia.<sup>8,9</sup> In September 1969, Alican et al. performed another intestinal transplant in a boy with an ileal segment withdrawn from his mother. The rejected graft was removed after nine days and the patient died one month later. Okumura performed the second intestinal transplant in October 1970. The graft was removed seven days later due to rejection and the patient died seven days after graft removal.<sup>10</sup> Fortner et al. (1970) performed an intestinal transplant using a 170 cm-long graft from the patient's human leukocyte antigen (HLA)-identical sister. Sixty days after transplantation, a graft biopsy showed severe mucosal lesions, which were thought to be capable of regeneration. However, the patient died on day 79 from gastrointestinal bleeding.<sup>11</sup>

Until 1970, only eight clinical cases of small intestinal transplantation had been reportedly performed world-wide. Patients died of technical complications, sepsis, or rejection.<sup>12</sup> Grafts came from cadavers in five instances and from living donors in three. Two of the five cadaver grafts included the right colon and the preservation solutions used were Ringer's lactate in four and Dextran in one. Venous return from the graft was drained into the systemic

circulation in seven of the eight cases. All patients died and graft survival ranged from 12 hours to 79 days. Immunosuppression was based on steroids and azathioprine in all cases. In addition, anti-lymphocytic globulin was given to the last five patients.

In 1989, Starzl et al. reported the first multivisceral transplants performed in two children with short-gut syndrome and secondary liver failure. The stomach, small intestine, colon, pancreas, and liver were transplanted. The first patient died perioperatively, but the second lived for more than six months before dying of an Epstein-Barr virus (EBV)-associated lymphoproliferative disorder that caused biliary obstruction and lethal sepsis. Evidence of graft rejection or graft-versus-host disease (GVHD) was never found in the long-surviving child. The constituent organs of the homograft functioned and maintained their morphological integrity throughout the 193 days of survival.<sup>13</sup> Following these two cases, the same group reported five cases of intestinal transplantation (three children, two adults), one as an isolated small intestine graft and the other four liver-intestine grafts, in 1992.<sup>14</sup>

## ■ SHORT BOWEL SYNDROME

Intestinal failure is a condition in which patients are incapable of maintaining proper nutrition and hydration through normal oral intake alone because of a reduction in the functional intestinal area. Worldwide, the leading cause is short bowel syndrome (SBS) as a result of surgical intestinal resection, but which also can be caused by radiation enteritis, chronic intestinal pseudo-obstruction, and congenital villous atrophy.<sup>15,16</sup>

The first recorded massive intestinal resection took place in 1880 in a patient who survived after the loss of two meters of bowel. In 1935, an outcome analysis of 257 patients with intestinal resection > 200 cm concluded that 33% of intestinal length could be removed without serious consequences. A 50% upper limit of safety was recommended.<sup>17</sup> However, it is now clear that not only remnant bowel length, but also specific anatomy and health play important roles in the degree of post-resection intestinal function.<sup>18</sup> The main causes of intestinal failure in adults and children are depicted in Table 1.

The clinical impact of SBS is far-reaching because these patients report lower health-related quality of life (QOL)

**Table 1 - Leading Causes of Intestinal Failure in Children and Adults**

Children	Adults
Intestinal atresia	Crohn's disease
Gastroschisis	Superior mesenteric artery thrombosis
	Superior mesenteric vein thrombosis
Crohn's disease	Trauma
Microvillus involution disease	Desmoid tumor
Necrotizing enterocolitis	Volvulus
Midgut volvulus	Pseudo-obstruction
Chronic intestinal pseudo-obstruction	Massive resection secondary to tumor
Massive resection secondary to tumor	Radiation enteritis
Hirschsprung disease	Familial polyposis
Pseudo-obstruction	Budd-Chiari syndrome
Megacystic colon	Gardner syndrome
Malrotation	

than the general population. Extensive resections may lead to malabsorption of micro- and macro-nutrients, malnutrition, hydroelectrolytic imbalance, severe diarrhea, and dehydration. These can lead to weight loss, confusion, difficulty concentrating, somnolence, and weakness. Associated symptoms such as apathy, depression, and irritability may impair recovery.

Water and sodium deficiencies, especially in patients with resected colons, can also lead to hypotension and kidney failure. These patients are susceptible to magnesium deficiency, which can contribute to increased fatigue and depression, muscle weakness and dysfunction, cardiac arrhythmias, and seizure. Also, patients with SBS are at increased risk for infection and impaired wound healing. Protein-calorie malnutrition associated with Vitamins A and C, zinc, copper, and selenium deficiencies delay wound healing.<sup>19-24</sup>

**■ THERAPY**

Patients with SBS must be treated in order to survive. An interdisciplinary, comprehensive, organizational approach is the recommended worldwide paradigm for managed care of patients with intestinal failure associated with SBS. Modality of therapy, dietary counseling, clinical and pharmacological approach, enteral and parenteral nutrition, surgical rehabilitation, and intestinal transplantation will depend on the analysis of several factors, such as extension of remaining gut, impossibility of receiving nutrients by mouth or feeding tube, primary disease, failure of total parenteral nutrition (TPN), and impossibility of intestinal rehabilitation through surgery. If all of these treatment types fail, the last option for life-saving indications is intestinal transplantation.

Patients with SBS differ in their pathology, remnant bowel anatomy, and demographic characteristics. For these reasons, guidelines from the Small Bowel and Nutrition Committee of the British Society of Gastroenterology recommend that patients with SBS be individually managed. Management using an interdisciplinary approach at specialized intestinal care centers of excellence is the ideal and best alternative, as these centers can provide optimal use of existing therapies.<sup>25</sup>

Gastrointestinal tract rehabilitation involves restoration of nutritional autonomy with an unrestricted oral diet and elimination of the need for intravenous nutritional support.

**Diet**

The dietary regimen is an essential component of any therapeutic strategy for intestinal rehabilitation with the aim to maximize absorption and reduce output. Consumption of small, frequent meals and avoidance of simple sugars help to decrease the intraluminal hyperosmotic load. When the colon is connected to the proximal bowel, the patient’s diet should contain 60% complex carbohydrates, 20% protein, and 20% fat with no fat restriction in the absence of a

functioning colon.<sup>26</sup> Viscous or soluble fibers from food sources with additional supplements if needed are indicated. Undigested fiber and carbohydrates will be metabolized into short-chain fatty acids with a significant caloric increase absorbed from the colonic mucosa. Also, soluble fibers increase the viscosity of the ostomy effluent and prolong transit time.

Maintenance of adequate oral hydration is achievable using solutions with 90 mEq Na and 20 g glucose/L. The solution tries to utilize the active co-transport system of sodium and glucose on the brush border.<sup>28</sup> Vitamin and mineral deficiencies, particularly vitamin B12, fat soluble vitamins, calcium, magnesium, and zinc are common in patients with SBS. Vitamin and mineral supplementation in doses exceeding dietary references are then required for these patients.

The specific resected area of intestine influences absorption. Loss of the duodenum and terminal ileum will impair absorption more than loss of the jejunum. Vitamin B12-intrinsic factor (needing supplementation) and bile salts are absorbed in the distal 100 cm of the ileum. When unabsorbed bile salts come into contact with the colonic mucosa, secretory or cholerrheic diarrhea is the result. If >100 cm of the terminal ileum is removed, the bile salt pool cannot be maintained because intestinal losses exceed the synthetic capacity of the liver. Steatorrhea tends to be severe, and secretory diarrhea can occur as a result of unabsorbed long-chain fatty acids coming into contact with the colon.<sup>29</sup>

Preservation of the colon is important for absorption of water, electrolytes, and fatty acids. It also plays a role in prolonging intestinal transit and stimulating intestinal adaptation. The ability of the patient to remain autonomous from TPN or intravenous (IV) fluids not only depends on the length of the small bowel, but also on the presence or absence of the colon.

Nutritional management of intestinal and multivisceral transplant recipients is at best incomplete without a comprehensive educational program to educate the patients on food safety, healthy food choices, and weight management. The goal is to interrupt TPN so the patient can enjoy an unrestricted oral diet rich in nutrients as well as flavor.

**■ INTESTINAL ADAPTATION**

After surgical resection, the remaining bowel undergoes adaptive changes to compensate for the loss of absorptive surface area, widening the circumference and increasing the villus height to restore absorptive function.<sup>30</sup> The intestine slightly hypertrophies and lengthens.<sup>31</sup> Up-regulation of the peptide transporter PepT1 in the colons of patients with SBS has been observed. This finding suggests that the colon can increase the luminal transport of di- and tri-peptides derived from the diet of other sources. The exact time frame of the adaptation process is thought to begin after surgery and continue for about two years. The intestinal adaptation progress of patients with SBS can be classified in phases (Table 2).

**Table 2 - Intestinal Adaptation Progress in Patients with SBS**

Phase	Duration (months)	Symptoms	Treatment
1	1-3	Severe diarrhea; limited absorption	Full nutrient and fluid support with parenteral nutrition (PN)
2	3-12	Absorption improves	PN reduction
3	12-24	Maximal adaptation	PN further reduced or stopped

**Table 3 - Grade of Intestinal Failure According to Daily Need for Parenteral Support**

Parenteral Support	Severity of Intestinal Failure (1 = borderline ... 5 = very severe)				
	Grade 1	Grade 2	Grade 3	Grade 4	Grade 5
Volume (ml/kg/day)	<17	17 – 34	34 – 51	51 – 68	≥ 68
Calories (kJ/kg/day)	<17	17 – 51	51 – 83	83 – 117	≥ 117
Sodium (mEq/kg/day)	<1.7	1.7 – 3.4	3.4 – 5.1	5.1 – 6.8	≥ 6.8
Potassium (mEq/kg/day)	<0.4	0.4 – 0.8	0.8 – 1.2	1.2 – 1.7	≥ 1.7
Magnesium (mMol/kg/day)	<0.08	0.08 – 0.17	0.17 – 0.25	0.25 – 0.33	≥ 0.33
Calcium (mMol/kg/day)	<0.07	0.07 – 0.10	0.10 – 0.13	0.13 – 0.17	≥ 0.17

For a 60 kg patient, the total volume mL/day for grade 1-5 is: < 1000, 1000-2000, 2000-3000; 3000-4000, and ≥4000, respectively. Modified from: Jeppesen PB. Short bowel syndrome: characterization of an orphan condition with many phenotypes. *Expert Opinion in Orphan Drugs* 2013; 1:515-25.<sup>35</sup>

To grade the severity of SBS, a daily need for parenteral support score was proposed, taking into account the volume, caloric content, and electrolytes needed to maintain an equilibrated organic and functional balance (Table 3).

The most prominent symptom in patients with SBS is diarrhea from multifactorial causes, including accelerated intestinal transit, gastric acid hyper secretion, intestinal bacterial overgrowth, and malabsorption of salts and bile salts. The debilitating nature of chronic severe diarrhea justifies efforts to mitigate the symptoms with an expected positive impact on the lives of affected patients. As a consequence, patients may need multiple medications to effectively control fecal output. Antidiarrheal drugs include anti-motility agents, anti-secretory drugs, probiotics, antibiotics, bile acid-binding enzymes, and pancreatic enzymes. SBS-associated malabsorption should be considered a major challenge to the optimization of an antidiarrheal regimen because drug absorption is impaired.<sup>33</sup> The goal, more than simply alleviating SBS-associated symptoms, is to introduce newer trophic therapies to enhance the absorptive capacity of the remnant bowel by augmenting the endogenous process of intestinal adaptation. Two currently FDA (USA)-approved pharmacologic therapies for SBS patients who are dependent on parenteral nutrition are: teduglutide, a glucagon-like peptide-2 analogue, and somatotropin, a recombinant form of human growth hormone.<sup>34</sup> Glucagon-like peptide -2 is produced in the ileum and colon by L cells and functions by enhancing small and large intestinal villus/crypt cell growth, maintaining mucosal integrity, and increasing nutrient absorption. Somatotropin increases small bowel length, mucosal height, and glutamine and leucine transport. It has a net effect of reducing IV volume requirements and infusion frequency in patients with SBS.

**■ PARENTERAL NUTRITION**

Nutritional management is a keystone approach to SBS patients. Most are encouraged to eat as much as their health state allows. Some patients will achieve nutritional adequacy with oral or enteral feeding, whereas others may partially or totally depend on parenteral nutrition.<sup>36</sup>

The concept of feeding patients entirely by IV injection of nutritive fluids was attempted long before the development of TPN almost five decades ago. A classical publication unequivocally established that it was possible and practical to feed immature puppies entirely via the venous route for prolonged periods without compromises in growth and development when compared to animals receiving natural

foods by mouth. This study was the basis for application of the method to surgical patients.<sup>37</sup>

The major challenges to pass from the laboratory to clinical practice at that time were listed by Dudrick as:

1. Formulating complete parenteral nutrient solutions
2. Concentrating substrate components to five to six times isotonicity without precipitation
3. Demonstration of the utility and safety of long-term central venous catheterization
4. Demonstration of the efficacy and safety of long-term infusion of hypertonic nutrient solutions
5. Maintaining asepsis and antisepsis throughout solution preparation and delivery
6. Anticipating, avoiding, and correcting metabolic imbalances or derangements

Nutritional support is an amalgamation of art and science, as is the entire broad field of medicine. In the 1950s, clinicians were aware of the negative impact of malnourishment on morbidity, mortality, and outcomes. However, only a few believed in the necessity for adequate nutritional support to achieve optimal clinical results. The prevailing dogma in the 1960s was: *“Feeding entirely by vein is impossible; even if it were possible, it would be impractical; even if it were practical, it would be unaffordable”*.<sup>38</sup> Dudrick pointed out the key points of this same review article:

1. Three hundred and fifty years of basic and clinical research were prerequisite to the successful development of TPN after discovery of the circulation in 1616.
2. The first documentation that TPN could provide the sole nutritional support for growth, development, and metabolic support was demonstrated in Beagle puppies in 1966.
3. A major clinical nutritional problem today is that cancer patients are being treated with increasing aggressiveness while failing to adequately support them nutritionally.
4. Major impediments to developing TPN included unavailability of all required nutrients for intravenous use, necessity to concentrate nutrients for adequate provision within water tolerance, necessity for central venous infusion of the hypertonic formulation, development of central venous feeding technology, the ever-present threat of sepsis, and the challenges of avoiding and correcting metabolic imbalances.
5. Some of the legacies of TPN include the unequivocal demonstration of the relevance of adequate nutrition in achievement of optimal clinical results, the subsequent

stimulation for the enormously increased use and sophistication of enteral nutrition, the stimulation of ambulatory special nutritional support and the advancement of home health care, and the preservation of countless lives.

Today, TPN is a reality. However, despite its benefits, TPN is also a high-risk, high-cost, and potentially problem-prone therapy. In addition, psychosocial problems and financial constraints influence QOL, which is known to be poorer in patients with TPN-dependence compared with healthy populations or patients with other intestinal diseases not requiring TPN. The potential effects of TPN dependence on QOL are clinical, social, and economic.<sup>39</sup> Patients placed on TPN cannot escape the threat of TPN-related complications. Along with problems at the time of catheterization, long-term parenteral nutrition is beset by various complications. The major clinical risks for patients on TPN are:

- Catheter-related complications (sepsis, thrombosis, occlusion, pneumothorax)
- Venous thrombosis
- Metabolic bone disease
- Parenteral nutrition-associated liver disease (PNALD)
- Impaired sleep
- Fatigue
- Depression
- Body image issues

PNALD is demonstrated by abnormalities in liver function, occurring in 28%-64% of patients, and significant liver disease in up to 39%. Serial liver biopsies for TPN-dependent patients are recommended because liver function tests are not predictive of hepatocellular injury or fibrosis in this population.<sup>40</sup>

Because of these complications, weaning, reducing, or decreasing TPN could minimize long-term negative effects, including life-threatening catheter-related infections, venous thrombosis, liver failure, metabolic bone disease, and impaired QOL.

For patients at risk of life-threatening TPN complications, intestinal transplantation has emerged as the standard of care. The CMS definition of parenteral nutrition failure includes:

1. Presence of TPN-associated liver disease
2. Loss of central venous access (three to six ventral venous accesses in children and two to four central venous accesses in adults)
3. Recurrent catheter-related sepsis or a single episode of fungal sepsis
4. Recurrent bouts of severe dehydration or metabolic abnormalities<sup>41</sup>

## ■ SURGICAL REHABILITATION

As discussed, TPN prolongs life in patients with SBS but is not the ideal solution for patients with anticipated long-term survival. Intestinal remnant length and the presence or absence of the terminal ileum and ileocecal valve continue to be important prognosticators of nutritional therapy.

Surgery can play an important role in preventing, mitigating, and in some cases, reversing intestinal failure.

Prompt operative intervention, when indicated, plays a major role during the different phases of SBS. Surgical techniques entail preventive measures, conservative

approaches, bowel revascularization, and restoration of GI continuity.

Surgical options in patients with long-term intestinal failure include those designed to improve intestinal function and fall into four main categories:<sup>42</sup>

1. Correction of slow transit secondary to partial obstructions, blind loops, enteroenteric fistulas, or stenosis; Improvement of intestinal motility in cases of dilated bowel (tapering enteroplasty, longitudinal intestinal lengthening, and tailoring, serial transverse enteroplasty, intestinal plication)
2. Slowing intestinal transit in the absence of bowel dilatation (segmental reversal of the small bowel, isoperistaltic colonic interposition)
3. Increasing mucosal surface area (sequential intestinal lengthening, controlled tissue expansion)
4. Creation of valves

Briefly, intestinal tapering consists of reducing the circumference of the intestine by either imbrications or excision of redundant bowel along the antimesenteric border; stricturoplasty can be performed at the stenotic region of the intestine by means of a Heinecke-Mikulicz-type enteroplasty; artificial intestinal valves created by distal intussusception of a segment of small intestine; inversion of an intestinal segment creating a zone of anti-peristalsis; and lengthening by longitudinal transection of a segment of the intestine between the mesenteric and antimesenteric edges and anastomosis of these parallel intestinal segments, as described by Bianchi in 1980<sup>43</sup> (Figure 1A).

As part of the rehabilitative efforts, a new lengthening operation called serial transverse enteroplasty (STEP) has been described. At least two of the above mentioned techniques are only of historical interest because they either bring disproportionate risk of adverse events (creation of valves) or are inefficient<sup>45</sup> (Figure 1B).

Predictors of successful rehabilitation include:

1. Patient age
2. Distal versus proximal resection
3. Length and status of the remaining small bowel
4. Presence of the ileocecal valve and/or colon
5. Status of the abdominal visceral vascular structures including the patency of the superior mesenteric artery and mesentericoportal circulation

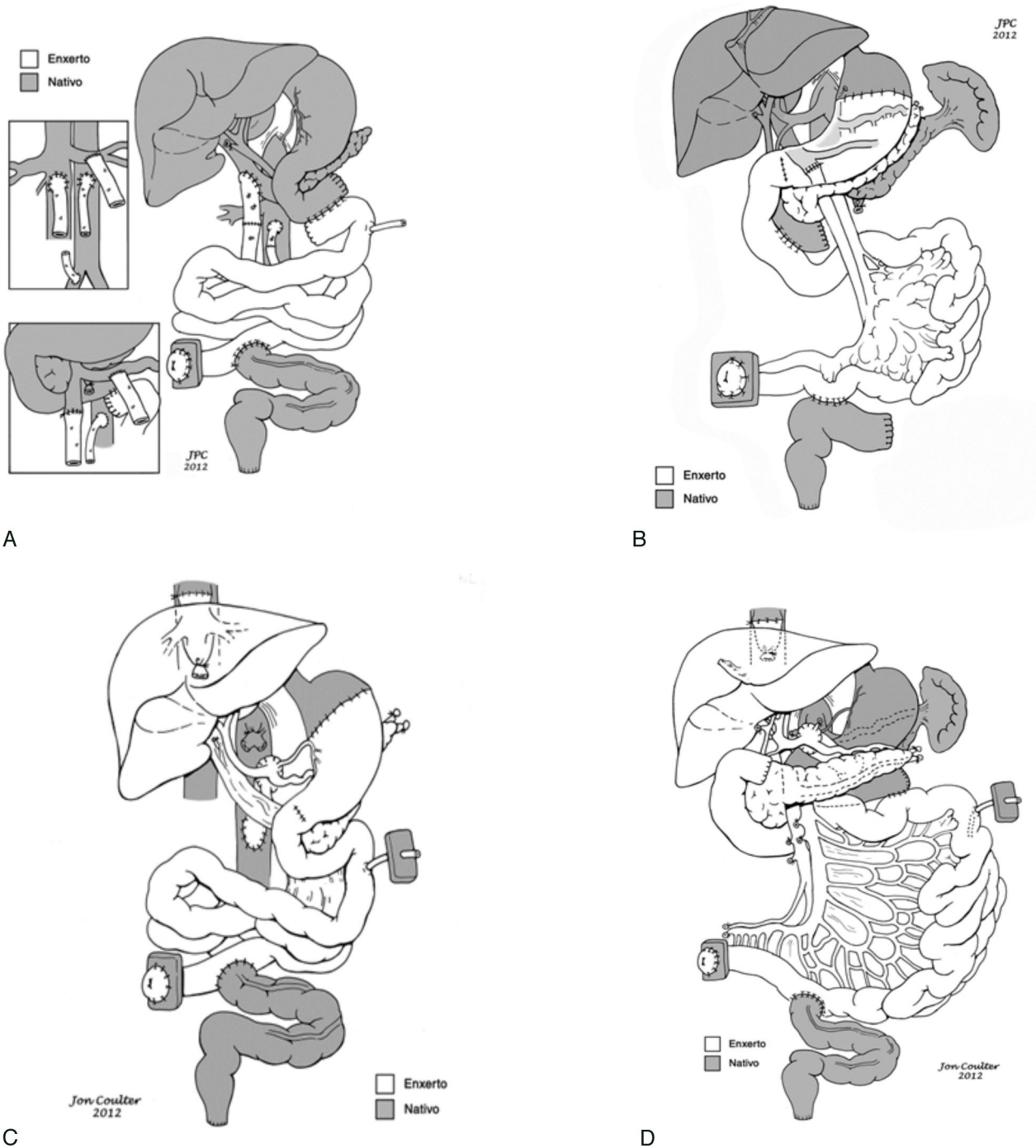
Favorable prognostic factors include:

1. Young age
2. Healthy residual bowel with intact absorptive and motility functions
3. Restored continuity of the gastrointestinal tract
4. Preservation of portions of the ileum, colon, as well as the ileocecal valve

The benefits of rehabilitation of biologic, physiological, and structural factors are determined by the ability to maximize absorptive capacity, slow transit time, restore physiologic interaction between the different abdominal visceral organs, and prevent intraluminal bacterial overgrowth.<sup>26</sup>

## ■ INTESTINAL TRANSPLANTATION

The successful development of clinical intestinal and multivisceral transplantation is one of the most important milestones in the recent history of organ transplantation.



**Figure 1 - A-** Intestinal loop lengthening, based on the longitudinal division of the intestine. **B-** Serial transverse enteroplasty (STEP) procedure aiming to enhance intestinal function in cases of short bowel syndrome. Modified from as described by Bianchi, 1980 (A) and Chang et al. 2006, with permission.

Over the last two decades, intestinal and multivisceral transplantations have become the standard of care as life-saving procedures for patients with irreversible intestinal failure who can no longer be maintained on IV nutrition and for those with complex abdominal pathology.<sup>46,47</sup> Early attempts at transplantation were hindered by technical and immunologic complications that led to graft failure or death. Fortunately, the results of intestinal transplantation have

improved over the past decade as a result of recent surgical advances, control of acute cellular rejection, and a decrease in lethal infections. The rate of patient survival at one year now exceeds 90% at experienced centers. Although long-term follow-up data are still lacking, the role of intestinal transplantation in the treatment of patients with gut failure is becoming clearer.<sup>48</sup>

## ■ INDICATIONS FOR TRANSPLANTATION

Intestinal transplantation is still limited to patients with combined irreversible intestinal and nutritional failure. The different causes leading to intestinal failure have already been discussed above and have also been the subject of many publications.<sup>49</sup>

Early referral for transplantation before development of TPN-associated liver failure allows the transplantation of liver-free isolated intestine graft. Although liver-containing intestinal graft seems to bring better immunologic outcome to the recipient, simultaneous hepatic replacement is only indicated for patients with advanced liver damage and severe cholestasis.<sup>46,47,49</sup> As a result, more patients have received isolated intestinal or modified multivisceral transplants with preservation of the native liver, including those with SBS, pseudo-obstruction, and Gardner syndrome. Saving the native liver reduces or eliminates the potential prohibitive risk of dying while on the USA United Network for Organ Sharing (UNOS) waiting list for a liver-containing allograft.<sup>50,51</sup> In addition, early transplantation is commonly associated with favorable outcome and better QOL.<sup>26,47,52</sup> An additional advantage is not losing the opportunity to perform, if necessary, allograft enterectomy to rescue the intestine-alone recipients with re-institution of TPN.<sup>53</sup>

It should be emphasized that current survival after transplantation is comparable to that of TPN-dependent intestinal failure patients, despite the use of the procedure as a rescue therapy. Of the 1,594 TPN patients followed by the OASIS registry in the early 1990s, those with benign intestinal diseases experienced 2.6 complications requiring hospitalization per year. Three-year survival ranged from 65% to 80%, depending on the cause of disease, of which 6.7% of the deaths were from TPN-related complications.<sup>54,55</sup> Of 200 patients with intestinal failure in the UK and Ireland, 34 have died. Ten (29%) died from TPN-related complications. Sepsis, major vessel thrombosis, and liver failure were the main causes of death in patients on TPN.<sup>56</sup> Equally important is the achievement of nutritional autonomy with better QOL and improved value of health care.<sup>57,58</sup>

## ■ CONTRAINDICATIONS

Contraindications for intestinal, liver-intestinal, and multivisceral transplantation have been established based on the accumulated experience in centers of excellence with organ transplantation. The list of the main contraindications includes:

1. Cardiopulmonary insufficiency
2. History or presence of systemic aggressive or incurable malignancy
3. Severe systemic autoimmune diseases
4. Acquired immunodeficiency syndrome
5. Life-threatening intra-abdominal or systemic infections
6. Patients over 60 years old, or with inactive lifestyle, and those who failed alcohol or drug rehabilitation

Age does not contraindicate transplantation, nor does the presence of malignancies treated and considered cured in the past. In addition, there have been reports of patients in which an incidental localized cancer was found during the transplant surgery, which did not preclude the transplantation procedure. CMS excludes facilities that fail to consider

individual contraindications in selecting patients for the procedure.<sup>59</sup>

## ■ PRE-TRANSPLANT EVALUATION

Candidacy for intestinal and composite visceral transplantation is usually determined after a thorough assessment of the gastrointestinal tract, solid abdominal organs, and other body systems. Nutritional status and residual gut functional capacity are studied. Failure to interrupt TPN in the presence of proper management for dieting and pharmacologic manipulation is a good marker of poor gastrointestinal functional reserve. Presence of primary enterocyte diseases is an indication for radiologic, endoscopic and histologic examination of the remaining GI tract. Pseudo-obstruction requires motility studies to define the extent of the syndrome. Patients with thrombotic disorders must submit to abdominal visceral angiography and undergo a full battery of hematologic tests to better evaluate thrombophilia and its extension. Also, radiologic imaging of the central venous system is essential to obtain an adequate venous access at transplant surgery.

The status of hepatic function is of fundamental importance to determine the type of graft modality to be used. Biochemical alterations of the hepatic enzymes and long-term use of TPN are indications for liver biopsy. Study of hepatic vessel patency, degree of portal hypertension, and coexistence of any other abdominal organ disease is mandatory. Finally, evaluation of the cardiopulmonary and other body systems is guided by age, complexity of medical and surgical history, and nature of the primary disease. Psychological preparation of adult and child patients is paramount and should include preparation for a stoma.<sup>60</sup>

## ■ INTESTINAL TRANSPLANTATION WAITING LIST

In July 2012, the number of programs, according to program-specific reports (PSRs) for intestinal transplantation, was 35 out of a total of 984 PSRs for all transplantation programs in 2012, including heart, kidney, liver, lung, and pancreas transplantation programs. Intestine procurement has increased since 2000, although the percentage of multi-organ donors from whom an intestine has been procured remains low. In 2011, 0.41 intestinal transplants per one million people were performed in the United States. The number of patients on the waiting list was 436; 17 patients from the list died, making the annual death-rate per 1,000 patient-years at risk 68.2. In 2002, the number of patients on the waiting list was 347 and 53 have died at a rate of 325.4.<sup>61</sup>

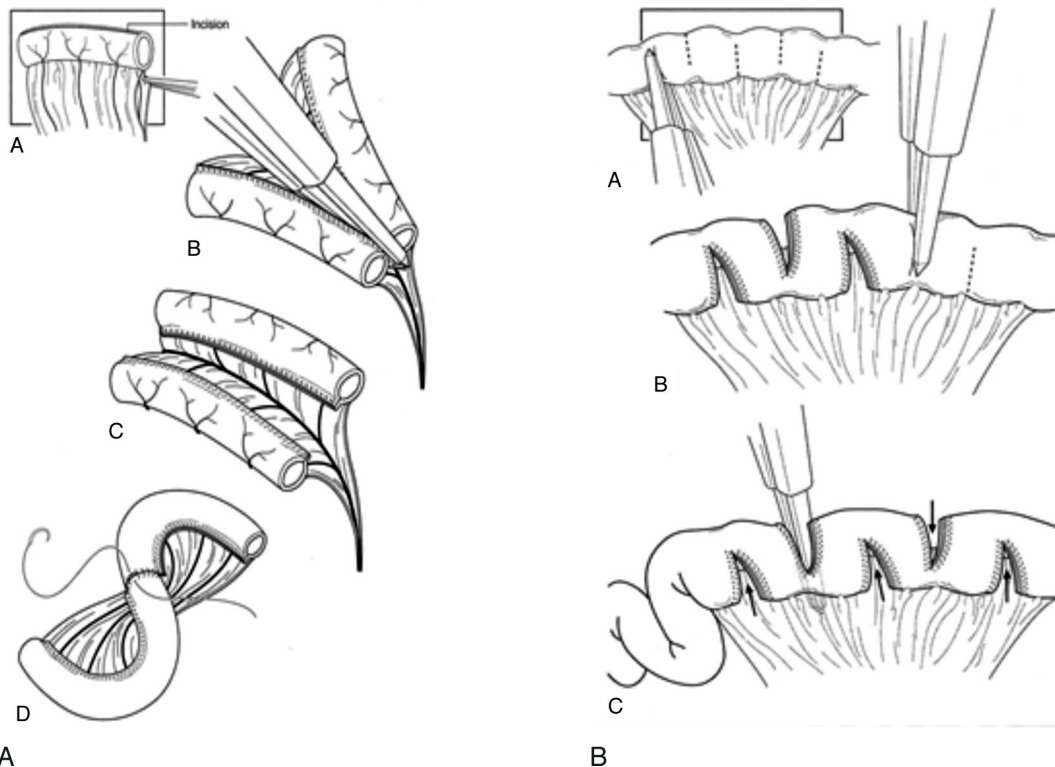
Intestinal transplant listings have increased significantly. The number of listings increased from 236 (1991-1995) to 1,161 (2001-2005). Death rates per 1,000 patient-years at risk for liver intestine (LI) transplants according to the Scientific Registry of Transplant Recipients analysis in May 2006 were 62.2 and 351.5 for pediatric isolated intestine (II) or liver-intestine (LI), respectively, and 153.2 and 475.8 for adult II and LI candidates, respectively.<sup>62</sup>

## ■ INTESTINAL TRANSPLANT MODALITIES AND NOMENCLATURE

The term "intestinal transplantation" includes a heterogeneous group of transplant options all taking advantage of the shared vascular supply that links together the digestive

abdominal organs. The different types of small bowel-containing allografts are depicted in Figure 2. The technical modalities can be summarized as:

1. Isolated intestine: the graft contains the small bowel connected to the main pedicle of superior mesenteric artery and vein. The vascular pedicle of the graft may be prepared as a Carrel patch or with separate stumps for the artery and vein. One alternative for this graft is the withdrawal of the small intestine *en bloc* with the colon and/or pancreas. After revascularization, intestinal continuity is reestablished proximally with the fourth portion of the duodenum or the stomach of the recipient. Distally, the small bowel or the right colon is anastomosed with the remaining left or sigmoid colon. In some conditions such as multiple polyposis or motility disorders extending into the rectum, an endo-rectal pull-through with sphincter preservation is indicated.
2. Liver + intestine: this graft contains the liver connected to the small bowel, with continuity being represented by the mesenterico-portal venous axis. Also, preserving the whole pancreas avoids the risk of pancreatic fistula. Retrieval of this graft *en bloc* with the colon and/or kidney is an alternative for technical reasons. Currently, the donor's pancreaticoduodenal complex, although optional, is commonly also maintained with the graft for technical reasons, as this prevents the occurrence of biliary fistulas. If necessary, mainly in pediatric patients, volume reduction of liver, small bowel, or both may be necessary to accommodate the graft into the abdominal cavity. The recipient surgical procedure requires the resection of all the native residual bowel and liver with preservation of the vena cava. After removal of the residual small bowel and colon, the native bile duct and hepatic artery are sectioned and ligated. The portal vein is clamped, cut, and anastomosed end-to-side to the recipient inferior vena cava or, alternatively, end-to-end with the donor's inferior vena cava after implantation. The vascular reconstruction is made with one arterial and one venous anastomosis for inflow and drainage of graft blood. Gastrointestinal reconstruction is achieved by anastomosing the first portion of the donor's jejunal loop to the donor bile duct (if the donor's duodenum and pancreas were not maintained) followed by anastomosis between the recipient duodenum to the allograft jejunum and completed with a distal anastomosis as described for the isolated graft.
3. Multivisceral: contains the liver, stomach, duodenum, pancreas, and small intestine. This graft can optionally be prepared *en bloc* with the colon and/or kidney. Also, it can be transplanted with or without the preserved native pancreaticoduodenal complex and/or spleen. Graft implantation requires only two vascular reconstructions: one arterial ideally using a conduit graft between the infrarenal aorta and graft superior mesenteric artery and the second between the donor's vena cava and recipient's hepatic veins. Pyloroplasty is always needed in the multivisceral as well as in the modified multivisceral grafts.



**Figure 2** - Technical modalities for transplantation of isolated intestine and multivisceral grafts. **A-** Isolated intestinal graft; **B-** Liver intestine graft with preservation of splenic/pancreatic/duodenal naive bloc; **C-** multivisceral graft. Note gastrogastic anastomosis, pyloroplasty, jejunostomy, ileocolonic anastomosis, and ileostomy. vascular reconstruction is performed joining naive and graft caval veins (piggy-back technique) and naive aorta to graft superior mesenteric artery **D-** Modified multivisceral graft with preservation of duodenal-splenic-pancreatic bloc. Note preservation of naive liver in this modality of transplantation.



4. Modified multivisceral: contains the stomach, duodenum, pancreas, and small intestine, but no liver. As with the multivisceral transplant, this graft may be withdrawn *en bloc* with the colon and/or kidney and the recipient's pancreaticoduodenal complex and/or spleen can be preserved. The crucial step is the preservation of the native hepatic arterial axis. The bile duct is cut and anastomosed to the jejunum. The dissection of the other organs proceeds the same as for multivisceral transplantation.

The described subtypes are optional depending on technical or medical factors. The nomenclature is not consistent among different authors. Some prefer using only the terms "isolated intestine transplants" and "intestine transplants that include the liver."<sup>63</sup> Preservation of the native spleen, duodenum and pancreas has the purpose of reducing the risk of infection and post-transplant lymphoproliferative disorders (PTLDs) and improving glycemic control. A native portocaval shunt is used in the case of multivisceral transplant, as already described for liver-intestinal transplant<sup>64</sup> (wherein the native splenoportal axis is left intact in the modified multivisceral transplant.<sup>50</sup>

Inclusion of the donor spleen in liver-intestine, multivisceral, and modified multivisceral transplants has been reported. The aim was to reduce the risk of infection and to promote tolerance. However, preservation of the donor spleen does not seem to increase the risk of GVHD nor does it offer significant protection against infections.<sup>65</sup>

Patients with renal failure may need a renal transplant associated with the intestinal transplant procedure, particularly in cases of retransplantation. The kidney graft can be transplanted *en bloc* with the liver-intestine or multivisceral graft, keeping the renal artery in continuity with the abdominal aorta or in a heterotopic standard fashion. In the first case, the renal vein is reconstructed end-to-side to the recipient's inferior vena cava.<sup>66</sup>

Historically, the terms "intestinal" and "multivisceral transplantation" originated more than half a century ago from the pioneering works of Lillehei and Starzl, with the third prototype liver-intestine transplant procedure being introduced in recent years.<sup>67</sup> The intestine, liver, and stomach are the defining organs referred to in the current nomenclature, with the intestine being the central core of any visceral allograft. "Multivisceral" is a distinctive term used for any stomach-containing allograft, with the terms "full" referring to the inclusion of donor liver and "modified" referring to exclusion of the donor liver.<sup>68</sup>

## ■ PRESERVATION SOLUTION

The two most used preservation solutions for grafts are University of Wisconsin solution (UW) and Histidine-Tryptophan-Ketoglutarate (HTK). HTK is a low-viscosity solution based on a buffer system (histidine) with two additional substrates (tryptophan and ketoglutarate). The buffering capacity of histidine slows the decrease in pH during the cold ischemia time of transplanted organs. The low viscosity may facilitate the diffusion and a faster cooling time. HTK has a low potassium content, which allows direct release into the patients' circulatory system. UW solution is more viscous, which flushes at a slower rate. Its preservation capacity is based on three principles: osmotic concentration maintained by metabolic inert substrates, additional

administration of the colloid carrier hydroxyethyl starch, and addition of oxygen radical scavengers. It is supposed to provide organ tolerance to long cold ischemia times in a predictable manner. Despite the concern that HTK can induce pancreatitis in composite intestinal grafts, this has not yet been proven. A study comparing the use of both preservation solutions in isolated intestine, liver-intestine, multivisceral, and modified multivisceral grafts demonstrated no difference in graft and patient survival at 30- and 90-days post-transplant. Also, no differences were found in initial function, endoscopic appearance, rejection episodes, or transplant pancreatitis.

## ■ ALLOGRAFT FUNCTION

Following transplantation, outcomes differ between patients who received an isolated intestine graft and those who received intestine plus liver. When adjusted for age, race, and diagnosis, post-transplant graft and patient survival data were superior for intestine-only recipients. The differences were more apparent at one year following transplantation, but diminished at subsequent time intervals. This could be explained by the fact that liver-intestine recipients were much sicker, as demonstrated by their higher waiting list mortality and also because they undergo more extensive surgery than do isolated intestine recipients. By five years after transplantation, the gap between the graft and recipients survival curves in both groups may reflect reduced graft loss due to chronic rejection in the liver-intestine recipients. Nevertheless, reported evidence of the liver's immunoprotective effect of the intestine graft may be noted in recipients receiving combined allografts in subsequent years, but is still difficult to demonstrate with the actual status of knowledge and deserves further investigation.<sup>62</sup>

In a published series of 376 patients (163 children and 213 adults) who underwent intestinal and multivisceral transplantation at the University of Pittsburgh, there were 149 non-five-year survivors and 227 who survived  $\geq$  five years. Enteric autonomy was achievable in 54% of non-five-year survivors and 92 of those who survived beyond five years. Of the 177 current survivors, 17 (10 pediatric and 7 adults) required TPN after allograft enterectomy in 10 or enteropathy in 7. The remaining 160 achieved nutritional autonomy, receiving an unrestricted oral diet. The mean pre-transplant body mass index was  $23 \pm 5$  and  $25 \pm 6$  post-transplant.<sup>52</sup>

The technical evolution of intestinal transplantation has evolved slowly but continuously over the years. Initial technical progress was directed at increasing the feasibility and safety of the procedure in the short term. More recent improvements were aimed at flexibility and long-term effects. The main recent technical trend is maximum preservation of native non-diseased organs of the recipient. The technical interest in intestinal transplantation has now moved to solutions that, despite possible increased difficulty, may offer better opportunities of mid-term and long-term success, both in terms of survival and QOL. Progress in the field of intestinal and multivisceral transplantation has occurred simultaneously with advances in immunosuppression protocols and more attention devoted to the QOL of patients.<sup>70</sup>

## ■ IMMUNOSUPPRESSION PROTOCOLS

The results of intestinal transplantation only became acceptable after the discovery and introduction of tacrolimus as an immunosuppressive agent in 1989. However, distinct protocols aiming to achieve better results evolved in the last 25 years. Type and number of adjunct immunosuppressants, as well as time of initiation of therapy, were the most important approach modifications.

For analytic purposes, the intestinal transplantation experience at the University of Pittsburgh, a well-known and qualified institution in organ transplantation, has been divided into three eras. In 2009, the eras represented a consecutive series of 500 transplants and were defined by introduction of new immunosuppressive strategies to enhance allograft acceptance:<sup>47</sup>

- Era I from 1990 to 1994. Immunosuppression was based on tacrolimus-steroid.
- Era II started in January 1995 with the initiation of a donor bone marrow augmentation protocol. In May 1995, induction therapy was added to the tacrolimus-steroid immunosuppression, initially with cyclophosphamide, which was replaced by daclizumab in May 1998. In April 2000, a clinical trial of low-dose *ex-vivo* allograft irradiation was initiated in adults. In addition, inclusion of the colon and transplantation of the intestine-only from cytomegalovirus (CMV)-positive donors into negative recipients was avoided. The newly-developed polymerase chain reaction (PCR) assay and the PP-65 antigenemia test allowed early monitoring, detection, and treatment of EBV and CMV infections, which fortified postoperative management.
- Era III began in July 2001 with a recipient preconditioning protocol with antilymphoid preparations and minimal post-transplant immunosuppression. Bone marrow augmentation and allograft irradiation continued until August 2003. This era has also witnessed aggressive use of reduced size allografts when *en bloc* colon transplant was revisited, and more liberal use of CMV-positive donors was adopted.

Tacrolimus-based immunosuppression has been used for all types of allografts so far. However, three distinct protocols evolved based upon type and number of adjunct immunosuppressants, as well as time of therapy initiation.

- Type I: Combined intravenous tacrolimus and steroid (bolus plus five-day taper) therapy was begun intraoperatively and gradually switched to oral doses. Azathioprine was added in selected cases. The regimen was used for all Era I allografts with high 12-hour target tacrolimus trough (20-30 ng/ml) during the first three months after transplantation. Rejection episodes were treated with high-dose steroids and/or OKT3 with adjustment of the daily tacrolimus dose to achieve trough levels. The same protocol was used in selected patients during both Eras II and III, but with a 121-hour target tacrolimus trough level of 15 to 20 ng/mL and 10 to 15 ng/mL, respectively.
- Type II: Induction therapy was added to the tacrolimus-steroid-based immunosuppression. Cyclophosphamide was used at the beginning of the experience and replaced by daclizumab thereafter. Azathioprine, mycophenolate mofetil, and rapamycin were used as a fourth drug. The 12-hour tacrolimus trough level was targeted at 15 to

20 ng/mL during the first three postoperative months with gradual dose reduction thereafter. Multiple maintenance drug therapy was common beyond three to six postoperative months. rATG was used to treat steroid resistance and severe rejection episodes.

- Type III: A preconditioning protocol of hematopoietic stem cell transplantation was introduced in July 2001 based on previous observations. However, bone marrow augmentation did not significantly affect the incidence of graft rejection, B-cell lymphoma, or the rate of GVHD severity.<sup>71</sup> A single dose of a lymphocyte-depleting agent and minimization of post-transplant immunosuppression were the two principles of this new protocol. The lymphoid depleting agents used were rATG (Thymoglobulin) or alemtuzumab and post-transplant immunosuppression used was tacrolimus monotherapy with avoidance, when possible, of maintenance steroid therapy. rATG was given in a single dose of 5 mg/kg which was infused over four to six hours and completed before reperfusion of the allograft, particularly in adult patients. Alemtuzumab was substituted for rATG in most adult patients with a single intravenous dose of 30 mg infusion over two hours upon induction of anesthesia. As a prophylaxis against cytokine release syndrome, intravenous steroids were given before and at the end of anti-lymphocyte antibody infusion. The intestinal and multivisceral recipients were the first transplant patients of any kind to be treated with such an innovative protocol. Tacrolimus alone was given within the first 24 hours after transplantation, with an initial intravenous or oral dose to achieve 12-hour drug trough level of 10 to 15 ng/mL by the third postoperative day. Such a level is nearly half of that targeted with Type I and II immunosuppression. The same level was aimed for during the first three postoperative months, after which levels of 5 to 10 ng/mL were sought. A variable course of dexamethasone or more commonly hydrocortisone was added for patients with T/B cell lymphocytotoxic cross-match and those who developed serum sickness syndrome, adrenal insufficiency, allograft rejection, and GVHD. The use of mycophenolate mofetil, rapamycin, or azathioprine was limited to recipients with recurrent episodes of rejection and those with tacrolimus-related complications.<sup>72</sup>

Stepwise reduction in the tacrolimus maintenance dose and frequency was initiated three to six months after transplantation in selected patients (stability with rejection-free state for more than 60 days and availability of recipient for at least four weeks of close follow-up after the last downward adjustment). The weaning was a slow stepwise procedure and the process was guided by clinical, endoscopic, histopathologic, and immunologic parameters. The aim was to achieve a 24-hour tacrolimus trough level of 5 ng/mL with undetectable levels at 48 and 72 hours from the last administered dose. Prompt reversal of the weaning process was initiated upon development of unexplained clinical and endoscopic changes with subtle histopathologic features suggestive of alloimmune activation.

A clinical trial of low-dose *ex-vivo* intestinal irradiation combined with donor bone marrow augmentation (3 to 5 × 10<sup>8</sup> cell/kg) was initiated in 2000.

## ■ SURGICAL TECHNICAL INNOVATIONS

Innovations in the surgical techniques in the donor and recipient and on the back table have strongly contributed to the improvement of results observed in intestinal transplantation, along with immunological development and more rational psycho-social support for transplanted patients. The most important surgical technique innovations during the period from the beginning of 1990 until now were as follows:

1. Use of vascular conduits for inflow and drainage of graft blood supply, namely the Carrel patch
2. Venous drainage of the graft to the recipient portal system
3. Initially temporary native portocaval shunts were maintained indefinitely
4. Preoperative embolization of native or graft arteries, aiming for decreased bleeding
5. Development of modified multivisceral transplant
6. Maintenance of anatomic integrity of the biliary tree in liver-intestine graft
7. Maintenance of the whole pancreas in liver-intestine graft
8. Graft reduction, allowing better accommodation in the abdominal cavity
9. Liver split in liver-intestine and multivisceral grafts
10. Development of pancreas-intestine graft
11. Biliary reconstruction in pancreas-intestine transplant modality
12. Preservation of native pancreatico-splenic duodenal complex in multivisceral and modified multivisceral transplants
13. Native duodenopancreatectomy with spleen preservation in modified multivisceral transplant
14. Possibility of inclusion of the colon in all types of grafts
15. Maintenance of native colonic conduit previously anastomosed to the duodenum.

## ■ COMPLICATIONS

Intestinal transplantation, being a complex procedure performed on a debilitated organism, is susceptible to different types of complications. They can occur at many steps during the whole process, beginning with the indication and patient selection for transplant, followed by patient physical and psychological preparation, donor, back table and recipient surgical procedures, application of a carefully-selected immunosuppression protocol, full time and intensive postoperative care, treatment of infection in a immunocompromised host, surgical wound and stoma care, reintroduction of a balanced oral diet, and weaning off long-term parenteral nutrition.

The indication for intestinal transplant must be discussed among members of the healthcare team and patient. The challenge is to identify long-term survival factors and search for new tactics to further improve patient and allograft longevity.

The main complications can be classified as:

1. Surgical technique-related: thrombosis of the arterial or venous vascular conduits or at the anastomotic site; pseudo aneurism of arterial graft; vascular graft rupture; aneurisms of native arteries; encephalopathy caused by systemic drainage of graft mesenteric blood; chylous ascitis or chylous abdominal collection;

- gastrointestinal anastomotic leakage; gastrointestinal bleeding (rejection being the most common etiology) also occurring at anastomotic sites or stomas; native gastric atony and pylorospasm; dysmotility of the intestinal allograft; internal hernia; biliary leaks; biliary obstruction by cholestatic or cholangitis syndrome; sphincter of Oddi dysfunction; pancreatic fistula; acute pancreatitis; chronic pancreatitis of the native pancreas; abdominal wall wound infection; peritonitis; loss of dominium; impaired wound healing
2. Rejection
3. Infections
4. Neuropsychiatric disorders: 24% of pediatric patients at the time of transplant, currently 18–34 years age, presented with a significant incidence of neuropsychiatric disorders compared to adult recipients. The manifestations observed were: hearing loss, developmental delay, major depression, and substance abuse and other axis I major mental disorders. Among adults, the main neuropsychiatric disorders were: bipolar disorders, depression, anxiety, impaired cognitive functions, hearing loss, and peripheral neuropathy
5. Recurrence of primary disease: Crohn's disease, desmoids tumors
6. Graft excision
7. Retransplantation

## ■ REJECTION

Rejection is the most important complication following intestinal and multivisceral transplantation. Acute rejection, occurring within 90 days after intestinal transplant, was seen in 92% of isolated small bowel graft recipients and in 66% of multivisceral allograft recipients. Interestingly, the rejection rate of the liver as a component of multivisceral graft was 43%, similar to the rejection rate observed in isolated liver transplantation.<sup>74</sup>

Monitoring of intestinal graft rejection is mainly based on clinical, endoscopic, histopathologic, radiologic, and immunologic criteria.

## ■ CLINICAL CRITERIA

### Acute Rejection

Clinical monitoring of the intestinal graft is accomplished by multiple daily clinical evaluations, focusing on the patient's general clinical status and on the patterns of the intestinal stoma. Acute rejection may be asymptomatic, but usually presents an array of unspecific symptoms such as fever, weakness, mood changes, abdominal pain, abdominal distension, hypoperistalsis, nausea and vomiting, diarrhea, or sudden increase of watery stoma discharge. The stoma may become edematous-erythematous, pale, congested, dusky, and friable. Stoma volume, consistency, presence of blood, and pH output may reflect issues besides rejection such as infection or malabsorption.

In more severe episodes of acute graft rejection, erosions, ulcerations, and sloughing of the intestinal mucosa may occur, with gastrointestinal bleeding, graft paralytic ileus, and absence of stomal output. Disruption of the normal intestinal mucosa barrier or bacterial or fungal translocation can develop, with consequent septic shock and/or acute respiratory distress syndrome-like conditions.

Clinical criteria are the keystone to early diagnosis of acute rejection of the intestinal graft, unlike rejection of other solid organ allografts in which diagnosis is mainly attained by biopsy. In intestinal and multiple visceral transplants, endoscopic, bioptic, radiologic, and metabolic parameters of acute rejection appear too late. They help to confirm, not make the diagnosis of acute rejection. Since only a few hours may be available to effectively and safely reverse the ongoing immunological injury, it would be a serious mistake to waste critical time waiting too long to start immunosuppressive treatment.

**Endoscopic Criteria.** Endoscopic evaluation is usually performed by terminal ileoscopy, but also by upper esophago-gastro-duodeno jejunoscopy and by lower colonoscopy. It is done twice a week for the first month, once a week for the next two months, monthly for the next three months, and every three to six months or whenever clinically indicated thereafter. Endoscopic features of mild to moderate acute intestinal graft rejection are edema of the mucosa, which can progress to focal or diffuse erythema, hyperemia, congestion, and dusky aspect. The graft can become hypoperistaltic and friable with fine granularity and focal erosions. More severe rejection presents with submucosal nodularity, focal or diffuse ulcerations, sloughing of extensive areas with development of pseudomembranes, bleeding, and no peristalsis. CMV enteritis constitutes the main differential diagnosis (punctate erythema, erosions, ulcerations).

**Histopathological Criteria.** In mild and moderate rejection, the lamina propria widens, with edema, inflammatory mononuclear infiltrate, and focal venulitis. The cellular infiltrate, composed of activated lymphoblasts and small lymphocytes, macrophages, plasma cells, eosinophils, and sometimes neutrophils, traverse the muscularis mucosae and invade the basal membrane with infiltration of the mucosal cellular layer. Cryptitis with apoptosis, goblet and Paneth cell depletion, epithelial cell necrosis, and various degrees of crypt loss can be seen. In the severe stage, complete mucosal sloughing, focal ulcerations, crypt destruction, neutrophil plugging of capillaries, granulation tissue replacement, and inflammatory pseudomembranes are found. The features in acute rejection can be focal. Differential diagnosis is difficult and should be formulated for intestinal graft ischemic injury and CMV enteritis.

**Radiologic Criteria.** Radiologic diagnosis is based on gastrointestinal contrast studies, CT scans, nuclear magnetic resonance imaging of the abdomen, and gastrointestinal transit and emptying time evaluations. Signs consist of dilatation of the intestinal lumen, edema and thickening of the intestinal wall, blunting and loss of the mucosal folds, and paralytic ileus with increased transit and emptying times.

**Immunologic Criteria.** Evaluation of rejection can be improved if some immunological features are considered: donor/recipient gender identity; identity, compatibility, or incompatibility of ABO blood type and HLA systems; positive and negative cross match, and percent of reactive antibody.

Prediction and early diagnosis continue to be major challenges in the absence of a reliable serum marker. Discovery of a highly-sensitive and specific marker would be a breakthrough in the field. Serum citrulline and fecal calprotectin have recently been proposed as noninvasive markers for acute rejection and allograft monitoring.<sup>75,76</sup>

The metabolomics of human intestinal transplant rejection have been recently described.<sup>77</sup> Proinflammatory mediator

leukotriene E4, vitamins B2, B5, and B6, and taurocholate were identified as reliable markers. Promising novel measures using gene expression profiles and T-cell alloresponses were also identified as viable molecular indicators.<sup>78</sup>

A recently published study suggests a strong association between circulating donor-specific anti-HLA antibodies and graft loss due to rejection, particularly chronic arteriopathy.<sup>79</sup>

## Chronic Rejection

Clinical presentation of chronic rejection consists of progressive allograft dysfunction with intermittent fever, worsening malnutrition, declining weight loss, long lasting exacerbating abdominal pain, recurrent or persistent intractable diarrhea, intermittent melena or enterorrhagia, and relapsing septic episodes.

Endoscopic examination shows the rigid, stiff, tubular, and hypokinetic appearance of intestinal loops, with thickening of the mucosa, flattening or atrophy of the mucosal folds, chronic ulceration with pseudo membranes, and intestinal bleeding.

Histology of mucosal biopsies shows a progressive distortion of the mucosal architecture with villous blunting, widening of the lamina propria, scant cellular infiltrate, severe prominent cryptitis with cryptic cell apoptosis, and depletion or loss of goblet and Paneth cells. In more severe and advanced stages focal chronic ulcerations, mucosal micro-abscesses, epithelial metaplasia, and fibrosis of the lamina propria, submucosa, and mesenteric lymph nodes along with obliterative arteriopathy of the intestinal arterioles occur, as demonstrated by full thickness intestinal biopsies.

Radiologically, intestinal contrast studies show a stiff, rigid, tubular picture of the intestinal loops, sometimes with strictures, flattening, or loss of the mucosal folds, or paralytic ileus with extended transit and emptying times. CT scans exhibit the same picture with significant thickening of the mucosa. Angiography reveals segmental stenosis of the mesenteric arterioles as a result of the obliterative arteriopathy.

## ■ GRAFT-VERSUS-HOST DISEASE

Graft-versus-host disease (GVHD) is a complication that can occur after a stem cell or bone marrow transplant in which the newly transplanted donor cells regard the transplant recipient's body as foreign and attack it. It is commonly associated with stem cell or bone marrow transplant, but the term also applies to other forms of tissue grafts.

Three criteria must be met in order for GVHD to occur.

- An immuno-competent graft is administered with viable and functional immune cells.
- The recipient is immunologically disparate - histo-incompatible.
- The recipient is immuno-compromised and therefore cannot destroy or inactivate the transplanted cells.<sup>80</sup>

Clinically, GVHD has been categorized as acute or chronic based on time of presentation. Any GVHD before day 100 is considered acute, and after day 100 it is considered chronic. GVHD severity is graded: acute GVHD is categorized as grade I-IV by modified Glucksberg criteria.<sup>81</sup> Acute and chronic GVHD remain major complications of allogeneic transplantation. Key issues regarding GVHD are noted below:

- The pathophysiology of GVHD is incompletely understood, but broadly involves an interplay of factors, including tissue injury from conditioning therapy, release of proinflammatory cytokines, and activation of antigen-presenting cells and alloimmune sensitization of effector T-lymphocytes that result in damage to GVHD target organs.
- GVHD prophylaxis involves improved HLA matching of donor and recipient, reduced conditioning regimen toxicity, and the use of pharmacologic agents such as methotrexate and calcineurin inhibitors (which may be superseded by alternative agents such as sirolimus, a mammalian target of rapamycin inhibitor).
- Initial therapy of established GVHD, both acute and chronic, remains dependent on the use of corticosteroids, despite their limited efficacy and significant toxicity.
- Standard of care is not well-established for therapy of steroid-refractory GVHD. Pharmacologic immunosuppressive agents (e.g., mycophenolate mofetil), biologic agents targeting effector immune cells (e.g., antithymocyte globulin) or proinflammatory cytokines (TNF- $\alpha$  blockade) have shown some efficacy, typically in early-phase studies.
- Supportive care, including symptom control and prophylaxis, early detection, and effective therapy of infections remain critical for good outcomes in GVHD patients.
- Novel therapeutic approaches, such as targeting of B-cells (e.g., rituximab), enhancement of regulatory T-cells (e.g., extracorporeal photopheresis), and cellular therapies (e.g., mesenchymal stem cells) that avoid the toxicity of generalized immunosuppression will likely play a prominent future role in GVHD therapy.
- Clinical trials testing novel agents (or novel combinations of agents) are critical for future advances in GVHD control.<sup>82</sup>

GVHD is monitored by clinical examination (fever, skin rash, septic-like syndrome), standard histology, immunohistochemical techniques (immuno-staining, sex identification after fluorescence-in-situ-hybridization – FISH), and PCR-karyotyping (“DNA finger-printing”). With these procedures, it is possible to differentiate migrating immunocompetent donor cells (donor “passenger leukocytes”) from recipient cells, as well as document the immunological injury of recipient tissues by infiltrating donor cells.

With time, it is possible to see gradual replacement of the donor hematolymphoid cells in the intestinal wall and mesenteric lymph nodes in the graft by immunocompetent hematolymphoid cells from the recipient, which rearranges the normal intestinal mucosal immune system architecture.<sup>83</sup>

GVHD was clinically observed in 38 (26 children and 12 adults) of 453 patients (8%). The allograft types were isolated intestine (n = 12), liver-intestine (n = 11), multivisceral (n = 12), and modified multivisceral (n = 3), with an overall incidence of 6%, 8%, 10%, and 14%, respectively. Circulating donor cells were detected in 25 patients. This analysis could not include the remaining 13 patients due to non-availability of discriminative monoclonal antibody at the time of transplant.<sup>47</sup>

## ■ INFECTION

Clinical presentation of infectious complications varies by infectious etiologic pathogen. Bacterial infections clinically present mostly as line sepsis, pneumonia, and wound and intra-abdominal abscesses. Multiple mixed infections from

the same source or separate multiple sources of infection may occur simultaneously. Fungal infections occur in the esophagus, peritoneal cavity, paranasal sinuses, or upper and lower respiratory system. Viral infections present in adults mainly as CMV enteritis, but CMV hepatitis, pneumonitis, gastritis, retinitis, and diffuse CMV syndrome may occur. Pediatric recipients seem more sensitive to EBV infection (PTLD and acute lymphadenitis). Microbial overgrowth and translocation are the main pathophysiologic features in this patient population. The promoting factors for ileal bacterial overgrowth are:

- Surgical manipulation with resultant ischemia and lymphatic disruption
- Absence of ileo-cecal valve
- Post-operative ileus
- High dose steroids and heavy immunosuppression
- Suppressed gastric acid barrier
- Temporary intravenous nutrition
- Defined formula diet

Translocation most commonly arises during acute rejection episodes which immunologically damage the normal mucosal barrier of the intestinal allograft. In summary, the high incidence of systemic infections found in the intestinal and multivisceral transplant population can be related to impairment of the host defenses (heavy immunosuppression), microbial translocation secondary to loss of the mucosal barrier (surgical manipulation, harvesting/preservation injury, rejection), and microbial overgrowth.

Infections must be monitored daily and should include frequent blood, sputum, bronchial, alveolar secretion, urine, surgical wound exudate, and drain fluid cultures. Quantitative cultures of stools and stomal discharge should be used to monitor significant changes in the intestinal microflora and confirm direct correlation between the onset of systemic infectious episodes and ongoing microbial overgrowth and translocation.

Among the 376 patients who underwent intestinal and multivisceral transplantation at the University of Pittsburgh, 148 (39%) received grafts from donors with positive serology for CMV infection. No statistical significance was observed when patients survived less (63, 42%) or more (85, 37%) than five years.

PTLD is a well-recognized complication of solid organ transplantation (SOT) and one of the most common post-transplant malignancies. In most cases, PTLD is associated with EBV infection of B-cells, either as a consequence of post-transplantation reactivation of the virus or from primary EBV infection. In cases of primary infection, EBV may be acquired from the donor graft or, less commonly, from environmental exposure. While T-cell lymphoproliferative disorders that are not typically associated with EBV infection also occur after SOT, the vast majority are B-cell proliferations.

PTLD is identified by a high index of suspicion in the appropriate clinical setting. The diagnosis is made by histopathological evidence of lymphoproliferation, commonly with the presence of EBV DNA, RNA, or protein detected in tissue. Most cases of PTLD occur within the first post-transplant year. The more intense the immunosuppression used, the greater the risk of PTLD and the earlier it tends to occur.

The incidence of PTLD varies with the type of transplanted allograft. Reported rates are higher in heart, heart-lung, and small bowel transplants compared with kidney and liver transplants. This presumably reflects in part the need for more intense immunosuppression to maintain certain types of allografts. Incidence of lymphoproliferative disease within the allograft itself also depends on the graft type. The lungs are frequently a site of involvement in patients undergoing heart-lung or heart-alone transplantation. Similarly, in small bowel transplants, the grafted bowel is commonly a site of PTLD. In cardiac transplants, the heart itself is seldom involved.

The American Society for Transplantation has recommended that the term "PTLD" also be applied to post-transplantation infectious mononucleosis and plasma cell hyperplasia (reactive hyperplasias) in addition to neoplastic disease.<sup>84</sup> When the term PTLD is not qualified, it refers to neoplastic disease. The 2008 World Health Organization classification system recognizes four major histopathologic PTLD subtypes: (1) early hyperplastic lesions, (2) polymorphic lesions (which may be polyclonal or monoclonal), (3) monomorphic lesions, and (4) classic Hodgkin's-type lymphomas.<sup>85</sup>

Whether PTLD presents as localized or disseminated disease, the tumors are often aggressive, rapidly progressive, and potentially life-threatening. Clinical presentation is variable and includes fever (57%), lymphadenopathy (38%), gastrointestinal symptoms (including obstruction [27%]), infectious mononucleosis-like syndrome that can be fulminant (19%), pulmonary symptoms (15%), central nervous system symptoms (13%), and weight loss (9%).

PTLD developed in 57 recipients in a series of 500 transplants performed on 453 patients. The disease was EBV-associated in 55 of those patients. The cumulative PTLD-free survival was significantly ( $P < 0.001$ ) better with induction therapy and recipient pretreatment and no PTLD developed after the fourth postoperative year. The reduced risk was also observed depending on the immunosuppression protocol to which the patients were submitted. Using multivariate analyses, era, immunosuppression, recipient age, and splenectomy were shown to be significant risk factors.<sup>47</sup>

The basis for initial management of PTLD is reduction or withdrawal of immunosuppression, which in some situations may reverse the lymphoproliferative process. This potential for reversibility with reduction of immunosuppression distinguishes PTLD from neoplastic lymphoproliferative disorders that occur in immunocompetent patients. Reduction of immunosuppression also carries the risk of inducing allograft dysfunction or loss and is not always feasible depending on the grafted organ or clinical situation. Other potential treatments include surgical excision of the lesion, localized radiation therapy, antiviral therapy, immunoglobulin therapy, combination chemotherapy, monoclonal antibodies, and the use of cytotoxic T-lymphocytes.

## ■ RETRANSPLANTATION

With increased practicality, visceral retransplantation with the same or more complex composite grafts is more frequently required as a life-saving procedure.<sup>79,87,88</sup>

Despite satisfactory outcomes, novel strategies are required to ameliorate the risk of recurrent immune destruction, particularly of the liver-free allograft.<sup>46,47</sup>

With intestine-alone allografts, a two-stage surgical strategy with a time interval between allograft enterectomy and retransplantation may achieve a better outcome.

A 2010 publication reported an overall 10% rate of retransplantation procedures involving the intestine in the USA. The primary indications for retransplantation were acute (31%) and chronic rejection (29%). Twenty-four percent of the patients died prior to hospital discharge and 72% were discharged alive with a functioning graft. However, 35% were discharged home with parenteral nutrition support. In unsuccessful cases, graft failure and sepsis were reported as the leading causes of patient death and rejection as the leading cause of graft loss.

Anti-B cell therapy, better HLA match, and simultaneous replacement of the native liver utilizing the domino procedure are novel approaches that could be utilized to reduce risk of recurrent rejection-induced graft loss.

Retransplantation in patients whose primary allografts were liver-free have showed a rejection rate of 90% to 100%, independent of the presence of liver in the second allograft. However, when both the primary graft and the second graft contained liver, the rejection incidence of the retransplant dropped to 50%.<sup>52</sup>

Pediatric patients showed that rejection after a second transplantation is comparable to that seen after a first transplant.

## ■ INTERDISCIPLINARY APPROACH

The continuing evolution and increased acceptance of the need for a rational, methodized, interdisciplinary approach to the management of patients with SBS and intestinal failure will lead to improved patient outcomes. The long-term strategy ideally will be anchored through specialized intestinal rehabilitation centers. In this way, all available measures of dietary, medical treatment modality, and surgical options can be employed to optimal effect with patient benefits of better understanding of the disease state, stabilized nutrient and fluid balance, control of symptoms and complications, and improved QOL.

With new tactics to further improve long-term survival, including social support measures, visceral transplantation patients have achieved excellent nutritional autonomy and good QOL.

## ■ COMMENTS AND CONCLUSIONS

Intestinal transplant outcomes have improved, but still lag behind those of kidney, liver, and heart. Treatment comes with a risk of sudden or gradual graft loss or mortality due to rejection, infection, and disease recurrence, even many years after transplantation. Complications, which are surmountable in other group of patients, may be fatal here.

It seems that inclusion of the liver protects the intestinal graft in the long-term, although early complications are more severe in multivisceral transplantation. Rejection (even early on), immunosuppression type, splenectomy, HLA mismatch, and female sex are significant risk factors for late graft loss.

The accumulated experience shows that lack of social support is a dominant risk factor for survival. This is an extremely important factor in the process of patient selection, as many of these evaluated babies and adults come from already broken families. The other important point in terms of better outcomes is the early referral of patients with intestinal failure for transplantation.

Intestinal transplantation shows worse performance in a long-term scenario, basically due to rejection, often when short-term results are excellent. Even with the possibility of a second transplant, the chronic rejection phenomenon leads to disappointing results, especially in adult patients, confirming observations that long-term management is difficult for these patients.<sup>63</sup>

Contrary to what happens in adult populations, retransplantation in children has shown excellent patient and graft survival (71% and 55%, respectively).<sup>84</sup>

Minimizing graft loss from chronic rejection and optimizing long-term immunosuppression management may improve long-term patient and graft survival. More data on long-term morbidity, nutritional autonomy, and QOL are needed to better determine the overall benefit that intestinal transplantation affords patients.

## RESUMO

Apesar das primeiras decepções, os três principais tipos de transplante visceral (isolado intestino, fígado, intestino, multivisceral) têm evoluído para tornarem-se o tratamento padrão para pacientes com insuficiência nutricional e patologia abdominal complexa. Aloenxertos viscerais foram avaliados em estudos clínicos, radiológicos, endoscópicos e histopatológicos. Funções de absorção do intestino transplantado foram avaliadas através de peso corporal, índice de massa corporal e escores "z", níveis séricos de albumina, vitaminas e oligoelementos, bem como através de medições de densidade mineral óssea. Rejeição de enxerto, infecção e insuficiência renal, são as principais causas de morte. Além disso, apoio social não-funcionante e progressão da doença primária contribuem para as taxas de mortalidade para além dos marcos de acompanhamento de cinco e dez anos. Eventos remotos, incluindo rejeição aguda pós-transplante, desordem linfoproliferativa e doença enxerto-versus-hospedeiro foram significativamente maiores em pacientes pediátricos.

Destinatários adultos estão sujeitos a maior incidência de malignidade, com recorrência da doença primária e saúde óssea prejudicada. As principais causas de morte são falha do enxerto, complicações da terapia, desordem linfoproliferativa, progressão da doença primária e outros, tais como o abuso de drogas, suicídio e falta de apoio. De um modo geral, o estado de saúde tem sido sustentado com êxito através de intervenções para tratar a hipertensão, diabetes, osteoporose e insuficiência renal.

Apesar de recorrência da doença e de morbidades relacionadas com imunossupressão a longo prazo, o estado de saúde da maioria dos sobreviventes tem sido mantido com intervenções bem sucedidas para tratar co-morbidades. Com a melhoria contínua nos índices de sobrevivência inicial ena eficácia de reabilitação a longo prazo, o transplante visceral deve ser considerado como a melhor opção terapêutica para pacientes com insuficiência intestinal grave.

## REFERENCES

- Carrel A. La Technique des anastomoses vasculaires et la transplantation des visceres. *Lyon Med.* 1902;98:859.
- Ullmann. Experimentelle Nierentransplantation. *Wien klin Wochft.* 1902;15:281.
- Lillehei RC, Goot B, Miller FA. The physiological response of the small bowel of the dog to ischemia including prolonged in vitro preservation of the bowel with successful replacement and survival. *Ann Surg.* 1959;150:543-60.
- Starzl TE, Kaupp HA Jr. Mass homotransplantation of abdominal organs. *Surg Forum.* 1960;11:28-30.
- Monchik GJ, Russel PS. Transplantation of small bowel in the rat: technical and immunological considerations. *Surgery.* 1971;70(5):693-702.
- Alican F, Hardy JD, Cayirli M, Varner JE, Moynihan PC, Turner MD, et al. Intestinal transplantation: laboratory experience and report of a clinical case. *Am J Surg.* 1971;121(2):150-9.
- Lillehei RC, Idezuki Y, Feemster JA, Dietzman RH, Kelly WD, Merkel FK, et al. Transplantation of stomach, intestine, and pancreas: experimental and clinical observations. *Surgery.* 1967;62(4):721-41.
- Okumura M, Fujimura I, Ferrari AA, Nakiri K, Lemos PC, de Andréa EA, et al. Transplante de intestino delgado. Apresentação de um caso. *Rev Hosp Clin Fac Med Sao Paulo.* 1969;24(1):39-54.
- Olivier C, Rettori R, Baur O, Roux J. Homotransplantation orthotopique de l'intestin grele et des colons droit et transverse chez l'homme. *J Chir (Paris).* 1969;98(4):323-30.
- Okumura M, Mester M. The coming of age of small bowel transplantation: a historical perspective. *Transplant Proc.* 1992;24(3):1241-2.
- Fortner JG, Shiu MH, Kunlin A, Gaston JP, Shils ME, Krumins S, et al. Orthotopic intestinal allografting after massive intestinal resection. *Bull La Soc Inter Chir.* 1972;31(4):264-71.
- Margreiter R. The history of intestinal transplantation. *Transplantation Reviews.* 1997;11:9-21.
- Starzl T, Rowe ML, Todo S, Jaffe R, Tzakis A, Hoffman AL, et al. Transplantation of Multiple Abdominal Viscera. *JAMA.* 1989;261(10):1449-57.
- Todo S, Tzakis AG, Abu-Elmagd K, Reyes J, Fung JJ, Casavilla A, et al. Cadaveric small bowel and small bowel-liver transplantation in humans. *Transplantation.* 1992;53(2):369-76.
- O'keefe SJ, Buchman AL, Fishbein TM, Jeejeeboy KN, Jeppesen PB, Shaffer J. Short bowel syndrome and intestinal failure: consensus definitions and overview. *Clin Gastroenterol Hepatol.* 2006;4(1):6-10.
- Buchman AL, Scolapio J, Fryer J. AGA technical review on short bowel syndrome and intestinal transplantation. *Gastroenterology.* 2003;124(4):1111-34.
- Haymond HE. Massive resection of the small intestine: an analysis of 257 cases. *Surg Gynecol Obstet.* 1935;51:693-705.
- Storch KJ. Overview of short bowel syndrome: clinical features, pathophysiology, impact, and management. *J parent Enteral Nutr.* 2014;38(Suppl 1):5S-7S.
- Kalaitzakis E, Carlsson E, Josefsson A, Bosaeus I. Quality of life in short-bowel syndrome: impact of fatigue and gastrointestinal symptoms. *Scand J Gastroenterol.* 2008;43(9):1057-65.
- Carlsson E, Bosaeus I, Nordgreen S. Quality of life and concerns in patients with short bowel syndrome. *Clin Nutr.* 2003;22(5):445-52.
- Sundaram A, Koutkia P, Apovian CM. Nutritional Management of short bowel syndrome in adults. *J Clin Gastroenterol.* 2002;34(3):207-20.
- Nightingale J, Woodward JM. Small Bowel Nutrition Committee of the British Society of Gastroenterology. Guidelines for management of patients with short bowel. *Gut.* 2006;55(suppl 4):iv1-12.
- Sriram K, Lonchyna VA. Micronutrients supplementation in adult nutrition therapy: practical considerations. *JPEN J Parenter Enteral Nutr.* 2009;33(5):548-62.
- Matarese LE. Nutrition and fluid optimization for patients with short bowel syndrome. *JPEN J Parenter Enteral Nutr.* 2013;37(2):161-70.
- Matarese LE, Jeppesen PB, O'keefe JD. Short bowel syndrome in adults: the need for an interdisciplinary approach and coordinated care. *JPEN J Parenter Enteral Nutr.* 2014;38(suppl 1):60S-4S.
- Abu-Elmagd K, Bond G, Matarese L, Costa G, Koritsky D, Laughlin K, Schuster B, Soltys K, Hossam K, Sindhi R, O'Keefe S, Mazariegos G. Gut rehabilitation and intestinal transplantation. *Therapy.* 2005;2(6):853-64.
- Nightingale JMD, Lennard-Jones JE, Gertner DJ, Wood SR, Bartran CI. Colonic preservation reduces need for parenteral therapy, increases incidence of renal stones, but does not change high prevalence of gallstones in patients with short bowel. *Gut.* 1992;33(11):1493-7.
- Fortran JS. Stimulation of active and passive sodium absorption by sugars in the human jejunum. *J Clin Invest.* 1975;55(4):728-37.
- Matarese LE, O'Keefe SJ, Kandil HM, Bond G, Costa G, Abu-Elmagd K. Short bowel syndrome: clinical guidelines for nutrition management. *Nutr Clin Practice.* 2005;20(5):493-502.
- Todo S, Tzakis A, Abu-Elmagd K, Reyes J, Starzl TE. Current status of intestinal transplantation. *Adv Surg.* 1994;27:295-316.
- Dowling RH, Booth DB. Functional compensation after small bowel resection in man. *Lancet.* 1966;2(7455):146-7.
- Messing B, Crenn P, Beau P, Boutroun-Ruault MC, Rambeaud JC, Matuschusky C. Long-term survival and parenteral nutrition dependence in adult patients with short bowel syndrome. *Gastroenterology.* 1999;117(5):1043-50.
- Kumpf VJ. Pharmacologic management of diarrhea in patients with short bowel syndrome. *JPEN J Parenter Enteral Nutr.* 2014;38(suppl 1):38S-44S.
- Jeppesen PB. Pharmacologic options for intestinal rehabilitation in patients with short bowel syndrome. *JPEN J Parenter Enteral Nutr.* 2014;38(suppl 1):45S-52S.

35. Jeppesen PB. Short bowel syndrome: characterization of an orphan condition with many phenotypes. *Expert Opinion in Orphan Drugs*. 2013;1(7):515-25.
36. Winkler MF, Smith CE. Clinical, social, and economics impact of home parenteral nutrition in short bowel syndrome. *JPEN J Parenter Enteral Nutr*. 2014;38(suppl1):325-75.
37. Dudrick SJ, Vars HM, Rawnsley HM, Rhoads JE. Total intravenous feeding and growth in puppies. *Fed Proc*. 1966;25:481.
38. Dudrick SJ. History of parenteral nutrition. *J Am Coll Nutr*. 2009;28(3):243-51.
39. Gillanders L, Angstmann K, Ball P, O'Callaghan M, Thomson A, Wong T, et al. A prospective study of catheter-related complications in HPN patients. *Clin Nutr*. 2012;31(1):30-4.
40. Naini BV, Lassman CR. Total parenteral nutrition therapy and liver injury: a histopathologic study with clinical correlation. *Hum Pathol*. 2012;43(6):826-33.
41. <http://www.cms.gov/medicare> Accessed May 31, 2014.
42. Thompson JS, Langnas AN, Pinch LW, Kaufman S, Quigley EMM, Vanderhoof JA. Surgical approach to short bowel syndrome. Experience in a population of 160 patients. *Ann Surg*. 1995;222(4):600-5.
43. Bianchi A. Intestinal loop lengthening – a technique for increasing small intestinal length. *J Pediatr Surg*. 1980;15(2):145-51.
44. Chang RW, Javid PJ, Oh JT, Andreoli S, Kim HB, Fauza D, et al. Serial transverse enteroplasty enhances intestinal function in a model of short bowel syndrome. *Ann Surg*. 2006;243(2):223-8.
45. Iyer KR. Surgical management of short bowel syndrome. *JPEN J Parenter Enteral Nutr*. 2014;38(suppl 1):535-95.
46. Grant D, Abu-Elmagd K, Reyes J, Tzakis A, Langnas A, Fishbein T, et al. 2003 Report of the Intestine Transplant Registry: a new era has dawned. *Ann Surg*. 2005;241(4):607-13.
47. Abu-Elmagd KM, Costa G, Bond GJ, Soltys K, Sindhi R, Wu T, et al. Five hundred intestinal and multivisceral transplantations at a single center: major advances with new challenges. *Ann Surg*. 2009;250(4):567-81.
48. Fishbein TM. Intestinal transplantation. *N Engl J Med*. 2009;361(14):998-1008.
49. Abu-Elmagd KM. Intestinal transplantation: indications and patient selection. In: Langnas AN, Goulet O, Quigley EM, Tappenden KA, editors. *Intestinal failure: diagnosis, management and transplantation*. Massachusetts, USA: Wiley-Blackwell; 2008; p. 245-53.
50. Cruz RJ Jr, Costa G, Bond G, Stein WC, Wu G, Martin L, et al. Modified "liver-sparing" multivisceral transplant with preserved native spleen, pancreas, and duodenum: technique and long-term outcome. *J Gastrointest Surg*. 2010;14(11):1709-21.
51. Cruz RJ Jr, Costa G, Bond GJ, Soltys K, Rubin E, Humar A, et al. Modified multivisceral transplantation with spleen-preserving pancreaticoduodenectomy for patients with familial adenomatous polyposis "Gardner's Syndrome". *Transplantation*. 2011;91(12):1417-23.
52. Abu-Elmagd KM, Kosmach-Park B, Costa G, Zenati M, Martin L, Koritsky DA, et al. Long-term survival, nutritional autonomy, and quality of life after intestinal and multivisceral transplantation. *Ann Surg*. 2012;256(3):494-508.
53. Abu-Elmagd KM. Intestinal and Multivisceral Transplant Waiting List: Clinical Management According to Allograft Type and Current Organ Allocation System. In: Kirk A, Knechtle S, Larsen C, Madsen J, Pearson T, editors. *Textbook of Organ Transplantation*. 1st Ed. Wiley-Blackwell.
54. Howard L, Heaphey L, Fleming CR, Lining L, Steiger E. Four years of North America Registry home parenteral nutrition outcome data and their implication for patient management. *JPEN J Parenter Enteral Nutr*. 1991;15(4):384-93.
55. Stokes MA, Irving MH. Mortality in patients on home parenteral nutrition. *JPEN J Parenter Enteral Nutr*. 1989;13(2):172-5.
56. Murghal M, Irving M. Home parenteral nutrition in the United Kingdom and Ireland. *Lancet*. 1986;2(8503):383-7.
57. Abu-Elmagd K, Bond G, Reyes J, Fung J. Intestinal transplantation: a coming of age. *Adv Surg*. 2002;36:65-101.
58. Abu-Elmagd KM. Intestinal transplantation for short bowel syndrome and gastrointestinal failure: current consensus, rewarding outcomes, and practical guidelines. *Gastroenterology*. 2006;130(2 Suppl 1):S132-7.
59. Abu-Elmagd KM, Reyes J, Fung JJ, Mazariegos G, Bueno J, Janov C, et al. Evolution of clinical intestinal transplantation: improved outcome and cost effectiveness. *Transplant Proc*. 1999;31(1-2):582-4.
60. Reyes J, Abu-Elmagd K. Small bowel and liver transplantation in children. In: Kelly DA, editor. *Pediatric liver disease*: Oxford, Blackwell Science Ltd; 1998; p. 313-31.
61. OPTN/SRTR Data as of December 4, 2012; available online at: <http://www.ustransplant.org>.
62. Pomfret EA, Fryer JP, Sima CS, Lake JR, Merion RM. Liver and intestine transplantation in the United States, 1996-2005. *Am J Transpl*. 2007;7(part 2):1376-89.
63. Mazariegos GV, Steffick DE, Horslen S, Farmer D, Fryer J, Grant D, et al. Intestine transplantation in the United States 1999-2008. *Am J Transplant*. 2010;10(4 Pt 2):1020-34.
64. Matsumoto CS, Fishbein TM. Modified multivisceral transplantation with splenopancratic preservation. *Transplantation*. 2007;83(2):234-6.
65. Kato T, Tzakis A, Selvaggi G, Gaynor JJ, Takahashi H, Mathew J, et al. Transplantation of the spleen: effect of splenic allograft in human multivisceral transplantation. *Ann Surg*. 2007;246(3):436-44.
66. Tzakis AG, Kato T, Levi DM, Defaria W, Selvaggi G, Weppler D, et al. 100 multivisceral transplant at a single center. *Ann Surg*. 2005;242(4):491-3.
67. Abu-Elmagd K. The history of intestinal transplantation. In: Papalois VE, Hakim NS, editors. *History and of organ cell transplantation*. VIII. London: Imperial College Press; 2003; p. 171-93.
68. Abu-Elmagd K. The small bowel contained allografts: existing and proposed nomenclature. *Am J Transplant*. 2011;11(1):184-5.
69. Mangus RS, Tector AJ, Fridell JA, Kazimi Marwan, Hollinger E, Vianna RM. Comparison of histidine-tryptophan-ketoglutarate and University of Wisconsin solution in intestinal and multivisceral transplantation. *Transplantation*. 2008;86(2):298-302.
70. Colledan M, Zanfi C, Pinna AD. Technical aspects of intestinal transplantation. *Curr Opin Organ Transplant*. 2013;18(3):291-7.
71. Abu-Elmagd K, Reyes J, Todo S, Rao A, Lee R, Irish W, et al. Clinical Intestinal Transplantation: new perspectives and immunological considerations. *J Am Coll Surg*. 1998;186(5):512-25.
72. Reyes J, Mazariegos V, Abu-Elmagd K, Macedo C, Bond G, Murase N, et al. Intestinal transplantation under tacrolimus monotherapy after perioperative lymphoid depletion with rabbit anti-thymocyte globulin (thymoglobulin). *Am J Transpl*. 2005;5:1430-6.
73. Starzl TE, Murase N, Abu-Elmagd K, Gray EA, Shapiro R, Egtesad B, et al. Tolerogenic immunosuppression for organ transplantation. *Lancet*. 2003;361(9368):1502-10.
74. Scotti-Foglieni C, Marino IR, Cillo U, Furukawa K, Abu-Elmagd K, Todo S, et al. Human intestinal multivisceral transplantation. In: D'Amico DE, Bassi N, Tedeschi U, Cillo U, editors. *Transplantation: procedures and management*. Paris: Masson Publishing Co; 1994; p. 235-54.
75. Hibi T, Nishida S, Garcia J, Tryphonopoulos P, Tekin A, Selvaggi G, et al. Citrulline level is a potent indicator of acute rejection in the long term following pediatric intestinal/multivisceral transplantation. *Am J Transplant*. 2012;12(Supl 4):S27-S32.
76. Sudan D, Vargas L, Sun Y, Bok L, Dijkstra G, Langnas A. Calprotectin: a novel noninvasive marker for intestinal allograft monitoring. *Ann Surg*. 2007;246(2):311-5.
77. Giralanda R, Cheema AK, Kaur P, Kwon Y, Li A, Guerra J, et al. Metabolomics of human intestinal transplant rejection. *Am J Transplant*. 2012;12(Supl 4):S18-S26.
78. Sindhi R, Ashokkumar C, Higgs BW, Gilbert PB, Sun Q, Ranganathan S, et al. Allospecific CD154+ T-cytotoxic memory cells as potential surrogate for rejection risk in pediatric intestine transplantation. *Pediatr Transplant*. 2012;16(1):83-91.
79. Abu-Elmagd KM, Wu G, Costa G, Lunz J, Martin L, Koritsky DA, et al. Preformed and de novo donor specific antibodies in visceral transplantation: long-term outcome with special reference to the liver. *Am J Transplant*. 2012;12(11):3047-60.
80. Billingham RE. Reactions of grafts against their hosts. *Science*. 1959;130(3381):947-53.
81. Przepiorka D, Weisdorf D, Martin P, Klingemann HG, Beatty P, Hows J, et al. Consensus conference on acute GVHD grading. *Bone Marrow Transplant*. 1994;15(6):825-8.
82. Koreth J, Antin JH. Current and future approaches for control of graft-versus-host disease. *Expert Rev Hematol*. 2008;1(1):111.
83. Iwaki Y, Starzl TE, Yagiashi A, et al. Replacement of donor lymphoid tissue in human small bowel transplant under FK-506 immunosuppression. *Lancet*. 1991;337:818-9.
84. Green M, Webber S. Posttransplantation lymphoproliferative disorders. *Pediatr Clin North Am*. 2003;50(6):1471-91.
85. Swerdlow SH, Webber SA, Chadburn A, Ferry JA. Posttransplant lymphoproliferative disorders. In: Swerdlow SH, Campo E, Harris NL, Jaffe ES, editors. *WHO classification of tumors of haematopoietic and lymphoid tissue*. Lyon: IARC; 2008; p. 343-50.
86. Garfin PM, Shapiro R. Posttransplant lymphoproliferative disease. [emedicine.medscape.com/article/431364](http://emedicine.medscape.com/article/431364), accessed on June 2nd, 2014, 2014.
87. Mazariegos GV, Soltys K, Bond G, et al. Pediatric intestinal retransplantation: techniques, management, and outcomes. *Transplantation*. 2008;86(12):1777-82.
88. Desai CS, Khan KM, Gruessner AC, et al. Intestinal retransplantation: analysis of Organ Procurement and Transplantation Network database. *Transplantation*. 2012;93(1):120-5.